



## Research

## OPEN ACCESS

# Observation of mange-like skin lesions in snow leopards (*Panthera uncia*) and prey species in Kyrgyzstan

Johanne Ferri-Pisani Maltot <sup>ID</sup><sup>1\*</sup>, Martin Gilbert <sup>ID</sup><sup>2</sup>, Claire Lambert <sup>ID</sup><sup>1</sup>, Bastien Chaix <sup>ID</sup><sup>1</sup>, Baktybek Azhybekov <sup>ID</sup><sup>3</sup>, Anne-Lise Cabanat <sup>ID</sup><sup>1</sup>

<sup>1</sup>Objectif Sciences International NGO, OSI-Panthera program, Geneva, Switzerland

<sup>2</sup>Cornell K. Lisa Yang Center for Wildlife Health, Cornell University, College of Veterinary Medicine, Ithaca, NY 14853, United States

<sup>3</sup>Kyrgyz National Agrarian University named after K.I. Skryabin 720005, O. Mederov St., 68, Bishkek, Kyrgyz Republic

## Abstract

**Background** Parasitic mites are widespread and affect various animal species globally. In naïve populations, they can cause significant enzootic diseases that threaten health and survival. *Sarcoptes scabiei*, the mite causing sarcoptic mange, has been reported in Siberian ibex (*Capra sibirica*) and suspected in snow leopards (*Panthera uncia*) which exhibited dermatological lesions and poor body condition.

**Objective** This study aimed to identify disease signs in animal species at the Sarychat-Eertash and Naryn Reserves in Kyrgyzstan, focusing on snow leopards and their prey. We analyzed camera trap images from the OSI-Panthera program to estimate the percentage of camera trap pictures showing animals exhibiting mange-like skin lesions.

**Methods** The OSI-Panthera program has been conducting non-invasive research involving placement of camera traps in the Sarychat-Eertash and Naryn Nature State Reserves in Kyrgyzstan since 2007 and 2016 respectively, to study and conserve snow leopards. Long-term camera trapping has enabled population monitoring while providing key information on signs of disease affecting the species and its prey.

**Results** Since 2012, camera trap images have revealed mange-like skin lesions on snow leopards, Altai marmots (*Marmota baibacina*) and Siberian ibexes. These include alopecia, presumed hyperkeratosis, scabs, deep fissures and dark grey discolouration of the skin. The detection rate of suggestive skin lesions varies considerably from year to year and depending on the study area for each of these species, ranging from 0% to 51.07%. While interpretation of images is limited by the lack of concomitant biological sampling and analysis, these detections raise concerns about the transmission and spread of diseases among animal populations and species within Kyrgyz protected areas.

**Conclusion** Given the current context of increasing risk of emerging diseases in Central Asia high-mountain ecosystems, our observations emphasize the need for further research to confirm the causative agents and to understand the impact of mange on species conservation.

**Keywords** Altai marmot | Kyrgyzstan | mange | Siberian ibex | snow leopard | skin lesion

## Introduction

The snow leopard (*Panthera uncia*) is an emblematic but endangered species, listed as Vulnerable by the International Union for Conservation of Nature (IUCN). Its elusive behaviour and remote habitat have led to a scarcity of health studies in the wild, and our understanding of the diseases affecting this species remains very limited (Ostrowski & Gilbert, 2016). In the past, snow leopards were considered at low risk for infectious outbreaks as they inhabit cold, dry climates

with sparse human density. However, climate change, globalization, and expanding human presence in the region are now creating conditions that increasingly favour the emergence of infectious diseases in high-mountain ecosystems of Central Asia (Mishra *et al.*, 2022). These pressures intensify contact among people, livestock and wildlife, while global warming, habitat fragmentation and the movement of pathogens further accelerate the likelihood of pathogen transmission.

\*Corresponding author Email: [johanne.fpm@gmail.com](mailto:johanne.fpm@gmail.com)

The OSI-Panthera program of the Objectif Sciences International (OSI) NGO has been implementing snow leopard research and conservation since 2006 by using non-invasive methods and sensitizing people to the need to protect the species and its ecosystem. This work has focused on two main areas in Kyrgyzstan, the Nature State Reserves of Sarychat-Eertash (SE) and Naryn, since 2012 and 2016, respectively. The NGO is collecting data in these places by setting and analysing camera traps, scat sampling, signs of presence surveys and wildlife counts. Since 2012, camera trap images have revealed mange-like skin lesions on several animals, including snow leopards, Altai marmots (*Marmota baibacina*) and Siberian ibexes (*Capra sibirica*).

This study aimed to identify signs of disease in various animal species found in the SE and Naryn Reserves in Kyrgyzstan, particularly focusing on snow leopards and their prey. To achieve this, we conducted a retrospective analysis of images captured by camera traps installed as part of the OSI-Panthera program. The study sought to estimate the percentage of images showing individuals with visible mange-like skin lesions for each species once they were detected. The ultimate goal is to guide future scientific research projects focused on wildlife conservation.

## Methods

### Study area

Both study areas are located in the Tien Shan Mountains in Kyrgyzstan (Figure 1). These are located on the Kyrgyz High Plateau, surrounded by hunting concessions and livestock pastures. The SE Nature State Reserve is located in the Issyk-Kul region (149,117.9 hectares) and is a high-mountain reserve (2,400 to 5,500 meters above sea level) bisected by the large valley of the Eertash River. The area includes a core (total reserve) and a buffer zone (where livestock herding is allowed) characterized by mountains, pastures, rocky areas and glaciers. The southern border of the reserve is located 18 km north of the village of Ak-Shyrak, and the village of Enylchek lies east of the border along the Uch-Kul River. In the northwest, the reserve border runs along the

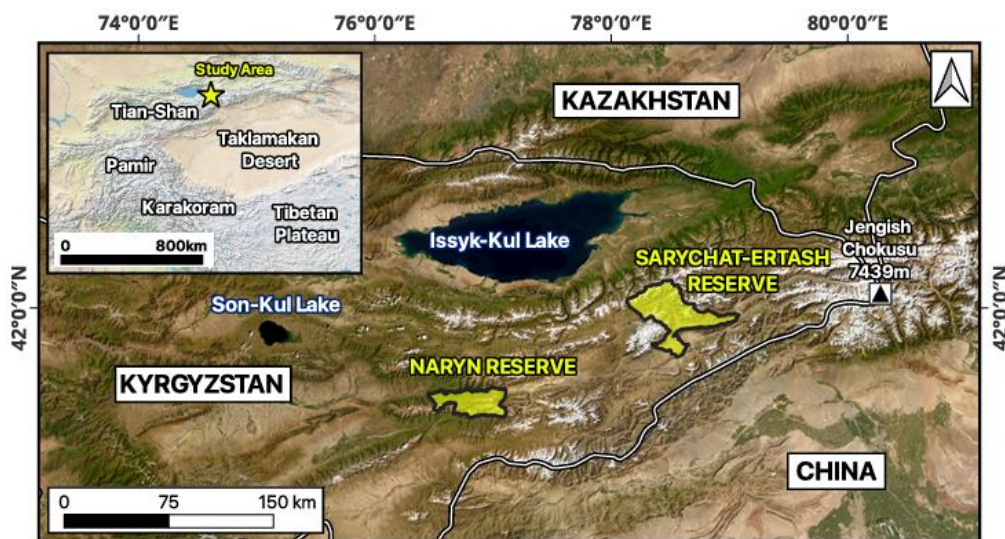
territory of the Kumtor Gold Mine. The Naryn Nature State Reserve (2,200–4,500 meters above sea level) also includes core and buffer zones and extends over 105,520 hectares between the Ulan River (east), the valleys of Tuyuk-suu, Iri-suu and Kok-bulak (west), the ridges of Jetim-too (north) and the rivers of Jangy-jer in the south. The reserve extends along both banks of the Naryn River, which is covered by spruce forests up to 3,000 metres on the northern slopes, with mountain pastures, rocky areas and glaciers elsewhere. The Reserve was designed in order to protect Schrenk's spruce (*Picea schrenkiana*) forest habitat and Tien Shan wapiti (*Cervus canadensis songaricus*).

### Camera trap setup and data collection

Approximately 50 camera traps (Bushnell E2 or E3 and Browning SPEC models) were set up (DEL infrared, lithium batteries, 16 to 32 GB SD cards) to monitor snow leopard populations and other species in the protected areas year-round throughout the study period. These were installed by volunteers under the supervision of a scientific educator in strategic places where significant signs of snow leopard presence (faeces, urine spots, scratch marks, footprints) had been observed, along with habitat and geographical features increasing the probability of capturing images. Following the Global Snow Leopard and Ecosystem Protection Program (GSLEP) recommendations, traps were placed approximately 5 km apart, depending on the topography. The study areas have expanded and evolved over the years. These were set in camera mode with a series of three photos at each burst, taken with a one-second interval. Traps were checked once a year to change batteries and retrieve SD cards for later analysis by volunteers.

### Data analysis

A retrospective analysis of all images captured by the camera traps enabled the determination of the proportion of photographs showing suggestive skin lesions in the three species studied (snow leopard, Altai marmot and Siberian ibex) in each reserve for each year. A picture was categorised



**Figure 1** Map of the study areas with locations of the Sarychat-Eertash and Naryn State Nature Reserves in Kyrgyzstan, OSI-Panthera (map produced by Vianney Houard).

as positive if skin lesions consisting of hair loss, hyperkeratosis, scabs or skin fissures could be clearly identified. Other mammal species such as argali, grey wolves, Tien Shan brown bears, Himalayan lynxes and Tolaï hares were not discussed here as none of the obtained images suggested any skin lesions. A statistical analysis of the data was then conducted using R software to assess variation in disease detection across species, years, and study areas.

## Results

### Snow leopard


A camera trap located in the SE Reserve captured images of a male snow leopard (named Aiperi) that was first recorded as an adult in 2016 and remained in the area thereafter. Prior to October 2021 (**Figure 2A**), no clear lesions were visible on the trap images of this animal. Then, in December 2021, hair density had decreased on the tail (**Figure 2B**), progressing to severe alopecia by January 1, 2022 (**Figure 2C**). On January 11, 2022, he presented with dark grey discolouration of the skin affecting the tail, and matted fur with hair loss on the back, flanks, limbs and on the face, which appeared swollen, especially around the right eye (**Figure 2D**). On January 28, 2022, a clear alopecia with grey-discoloured skin was visible on the back associated with increased hair loss on the flanks and the limbs. Other observations were suggestive of erythema on the right lateral and dorsal parts of the tail. Similar lesions were also apparent on alopecic areas on the right limbs and suspected on the left hind limb. Overall, skin lesions with progressive hair loss were detected during the winter of 2021-2022 over three months, on three different camera traps, until the snow leopard's last detection on January 28, 2022. Following the discovery of these images, a retrospective analysis of all the photographs taken by the camera traps was carried out, enabling the identification of other cases of snow leopards presenting with similar skin lesions involving hair loss, particularly on the tail. The proportion of

images in which suggestive skin lesions were observed varies but remains fairly low in this species, generally below 5% (mean 2.04%, median 0%). From 2012 in the SE Reserve, snow leopards exhibiting such skin lesions were observed in 2012 (visible in 21.05% of all snow leopard pictures), 2017 (4.60%), 2020-2021 (4.71%), 2022 (3.07%), 2023 (2.18%), and 2025 (4.22%). From 2016 in the Naryn Reserve, skin lesions were only detected in 2020-2021 (3.00%). Lesions that are regularly detected consist of decreased hair density, alopecia and dark grey skin discolouration. In all cases of snow leopards affected in our study, the distal part of the tail is the most affected area and is often the only visibly affected area when analysing camera trap footage. However, such lesions can also appear on other body parts, notably the back, face, flanks, and limbs. Skin lesions were only observed in adult snow leopards.

### Siberian ibex

Also in the SE Reserve, skin lesions were observed on ibexes. During summer 2014, a few-month-old young ibex was found dead by volunteers (**Figure 3A**), presenting with hair loss, severe hyperkeratosis, scabs, deep skin fissures and erythema, especially ventrally on the lower flanks, on the limbs, groin, and on the face around the eyes and on the muzzle (**Figure 3B**).

Then, in January 2018, a camera trap captured another ibex (adult female) in poor body condition exhibiting comparable lesions on the face, but especially proximally on the hind limbs and on the udder (**Figure 4A**). Next, in April and May (**Figure 4B**) 2022, the same camera trap captured further similar images of at least one adult male (maybe two) in poor body condition, exhibiting severe lesions on the face and hind legs. Elsewhere in the Naryn Reserve, in October 2022, a camera trap also captured an adult ibex in poor condition (**Figure 4C**), exhibiting extremely severe alopecia with hyperkeratosis, grey discolouration of the skin and scabs extended to the whole body.



**Figure 2** Snow leopard « Aiperi » detected on camera traps in the Sarychat-Eertash Nature State Reserve (OSI-Panthera program). (A) On October 18, 2021, no clear lesions could be seen. (B) On December 11, 2021, hair density had decreased on the tail. (C) On January 1, 2022, severe alopecia on the tail. (D) On January 11, 2022, dark grey discolouration of the skin affecting the tail, shaggy fur with hair loss, and swollen face.




**Figure 3** Siberian ibex found dead in the Sarychat-Eertash Nature State Reserve, summer 2014 (OSI-Panthera program). (A) Generalized skin disease with hair loss, severe hyperkeratosis, scabs, deep skin fissures and erythema, especially ventrally on the lower flanks, on the limbs and groin. (B) Severe hyperkeratosis, scabs, skin fissures on the face around the eyes and on the muzzle.

A retrospective analysis of all the photographs shot by the camera traps revealed other similar cases. From 2015 in the SE Reserve, ibexes exhibiting such skin lesions were observed in 2015 (lesions in 21.05% of all ibex pictures), 2018 (40.24%), 2019 (4.14%), 2020-2021 (3.61%), 2022 (31.42%), 2024 (2.95%), and 2025 (1.12%). From 2016 in the Naryn Reserve, skin lesions were detected in 2020-2021 (2.70%), 2022 (3.07%), 2023 (8.24%), 2024 (0.08%), and 2025 (1.25%). The proportion of pictures showing skin lesions in Siberian ibexes ranges from 0% to 40.24% (mean 6.31%, median 1.25%). Commonly observed lesions consist of alopecia with marked hyperkeratosis, scabs, skin fissures and dark grey skin discoloration. These lesions are found in both young and adult animals and affect the muzzle, the area around the eyes, and the ventral parts of the body (the limbs, the groin, the udder and the flanks).

Then, in January 2018, a camera trap captured another ibex (adult female) in poor body condition exhibiting comparable lesions on the face, but especially proximally on the hind limbs and on the udder (**Figure 4A**). Next, in April and May (**Figure 4B**) 2022, the same camera trap captured further similar images of at least one adult male (maybe two) in poor body condition, exhibiting severe lesions on the face and hind legs. Elsewhere in the Naryn Reserve, in October 2022, a camera trap also captured an adult ibex in poor condition (**Figure 4C**), exhibiting extremely severe alopecia with hyperkeratosis, grey discoloration of the skin and scabs extended to the whole body.

A retrospective analysis of all the photographs shot by the camera traps revealed other similar cases. From 2015 in the SE Reserve, ibexes exhibiting such skin lesions were observed in 2015 (lesions in 21.05% of all ibex pictures), 2018



**Figure 4** (A) Siberian ibex detected on camera traps in the Sarychat-Eertash (SE) Nature State Reserve, January 27, 2018 (OSI-Panthera program). Shaggy coat with hair loss, severe hyperkeratosis and many scabs. Lesions on hind limbs and udder. Poor body condition. (B) Siberian ibex (adult male) detected on camera trap in the SE Nature State Reserve, May 28, 2022 (OSI-Panthera program). Hair loss, severe hyperkeratosis, impressive scabs on the face, and marked blepharitis. Poor body condition. (C) Siberian ibex (adult) detected on camera trap in the Naryn Nature State Reserve, October 2022 (OSI-Panthera program). Severe alopecia with hyperkeratosis, scabs and grey discoloration extended to the whole body. (D) Siberian ibex (adult male) detected on camera trap in the Naryn Reserve, between July 2019 and July 2021 (OSI-Panthera program). Hair loss, severe hyperkeratosis, scabs and grey discoloration on the dorsal line, face, flank and proximal legs. Poor body condition.

(40.24%), 2019 (4.14%), 2020–2021 (3.61%), 2022 (31.42%), 2024 (2.95%), and 2025 (1.12%). From 2016 in the Naryn Reserve, skin lesions were detected in 2020–2021 (2.70%), 2022 (3.07%), 2023 (8.24%), 2024 (0.08%), and 2025 (1.25%). The proportion of pictures showing skin lesions in Siberian ibexes ranges from 0% to 40.24% (mean 6.31%, median 1.25%). Commonly observed lesions consist of alopecia with marked hyperkeratosis, scabs, skin fissures and dark grey skin discoloration. These lesions are found in both young and adult animals and affect the muzzle, the area around the eyes, and the ventral parts of the body (the limbs, the groin, the udder and the flanks).

### Altai marmot

Camera traps pictures highlighted visible skin lesions on Altai marmots in the Naryn Reserve between 2019 and 2022. In spring 2020 (precise date uncertain due to technical issues with the date stamps), images of at least one affected marmot were captured four times within a month (**Figure 5**) exhibiting severe alopecia with slate grey discoloration of the skin and presumed hyperkeratosis on the back, flanks, neck, lateral side of the limbs, top of the head, periorcular area and underneath. In June 2022, in the same reserve another camera trap captured an Altai marmot once with more extensive lesions extending distally to the carpal and tarsal joints. In May 2025, similar skin lesions were observed on at least one Altai marmot in the SE Reserve (**Figure 6**).

A retrospective analysis showed many cases of Altai marmots exhibiting such skin lesions, with significantly higher detection rates than in other species. From 2019 in the SE Reserve, similar skin lesions were detected in 2020–2021 (lesions in 39.77% of all Altai marmot pictures), 2022 (26.20%),

2023 (15.78%), 2024 (17.37%), and 2025 (12.10%). From 2016 in the Naryn Reserve, skin lesions were detected in 2016 (28.64%), 2017 (24.13%), 2018 (18.47%), 2019 (42.74%), 2020–2021 (14.03%), 2022 (40.82%), 2023 (43.80%), 2024 (51.07%), and 2025 (23.37%). The proportion of pictures showing skin lesions in Altai marmots ranges from 0% to 51.07% (mean 26.55%, median 24.13%). Commonly observed lesions consist of severe and diffuse alopecia with dark grey skin discoloration and presumed hyperkeratosis. These lesions are found in both young and adult animals and affect primarily the back, neck and flanks, but also the limbs, the tail, the area around the eyes and underneath.

## Discussion

### Differential diagnoses

Camera trap imagery alone is not sufficient to draw firm conclusions about the aetiological agents responsible for diseases in the sick animals detected. In the case of snow leopards, laboratory tests would be required to differentiate between the most likely differentials, including sarcoptic mange, notoedric mange, demodicosis or ringworm. Previously, cases of notoedric mange, demodicosis and ringworm have been reported only in captive snow leopards and involved clinical presentations different from those observed in our study (Arbaev *et al.*, 2017; Fletcher, 1978; Fletcher, 1980; Grob *et al.*, 2018). The lesions described in cases of ringworm due to *Microsporum* spp. were alopecic and erythematous spots measuring 1 to 3 cm in diameter, affecting especially the inner thighs, sacrum and tails (Arbaev *et al.*, 2017). Ringworm lesions due to *Trichophyton mentagrophytes* (Grob *et*



**Figure 5** Altai marmots detected on camera traps in the Naryn Nature State Reserve (OSI-Panthera program). (A) Detection between July 2021 and July 2022. Severe alopecia on the back and right flank, with slate grey discoloration of the skin and presumed hyperkeratosis. Hair loss around the right eye. (B) Detection between July 2021 and July 2022, 13 days after Figure 5 (A). Severe and extended alopecia with grey-discoloured skin and presumed hyperkeratosis on the back, left flank, neck, lateral side of the left limbs, top of the head, periorcular area and ventrally.



**Figure 6** Altai marmots detected on camera traps in the Sarychat-Eertash Nature State Reserve (OSI-Panthera program) on May 18, 2025. (A) Severe alopecia on the back and flank, with grey discoloration of the skin and presumed hyperkeratosis. Hair loss around the eye. (B) Severe alopecia on the back and flank, with grey discoloration of the skin and presumed hyperkeratosis. Hair loss around the eyes and dorsally on the tail.

*al.*, 2018) consisted of small focal alopecic areas on the face of two adults (asymptomatic young cubs). Notoedric mange has only been described in a litter of young captive snow leopards, leading to extensive hair loss due to pruritus on the face, head, neck and extending to the middle of the thorax. Alopecic areas were associated with erythema, excoriation, wrinkled grey crusts and moderate pyoderma (Fletcher, 1978). Demodicosis has been reported in a group of juveniles presenting with alopecia and brown-to-grey incrustations on the muzzle associated with moderate pyoderma (Fletcher, 1980). Based on the extent and severity of the lesions and the available literature, we hypothesise that infection with *Sarcoptes scabiei* could be responsible for the disease in the sick snow leopards we detected. Prior publications have referred to cases of sarcoptic mange-like signs in wild snow leopards in Pakistan (Pamir Times, 2011; Ostrowski & Gilbert, 2016), and in Nepal (DNPWC & DoFSC, 2024). Snow leopards are known to be susceptible to *Sarcoptes scabiei* (Kubanychbekov *et al.*, 2026; Ostrowski & Gilbert, 2016; Peters & Zwart, 1973), and while the clinical pattern of sarcoptic mange varies with species, individuals and environmental factors, previous reports have described similar lesions to those observed in our case. For instance, descriptions of sarcoptic mange in Himalayan lynx (*Lynx lynx isabellinus*) in Pakistan (Hameed *et al.*, 2016), coyotes (*Canis latrans*), gray wolves (*Canis lupus*) in Alberta (Bornstein *et al.*, 2001), and red foxes (*Vulpes vulpes*) in Norway (Carricondo-Sanchez *et al.*, 2017) are consistent with our observations on this snow leopard. Moreover, the incidence of sarcoptic mange often increases during winter (Pence & Ueckermann, 2002), and at the period when snow leopards descend to lower altitudes to hunt wild and domestic ungulates, potentially facilitating transmission. Finally, Aiperi's last camera trap detection in January 2022 raises concerns about his survival. Impaired

thermoregulation due to alopecia on his tail – given the tail's important role in conserving heat for this species, especially in winter – may have further exacerbated his poor condition.

In the case of Siberian ibex, laboratory analyses would also be required, with a potential differential list including mite infestations (*Sarcoptes*, *Psoroptes*, *Chorioptes*), lice, dermatophytosis, and bacterial skin disease. However, previous reports of sarcoptic mange in wild ungulates (Ostrowski & Gilbert, 2016), including Siberian ibex in Kyrgyzstan (Vyrypaev, 1985), Iberian wild goat (*Capra pyrenaica*) in Spain (León-Vizcaíno *et al.*, 1999), and blue sheep (*Pseudois nayaur*) in Pakistan (Dagleish *et al.*, 2007) describe lesions consistent with those observed in the sick Siberian ibexes we detected. Authors of previous reports associated these lesions with an intense pruritus that led to reductions in grazing, loss of flight behaviour, mobility issues, emaciation and even sometimes impaired vision. Based on studies in *Capra pyrenaica* (León-Vizcaíno *et al.*, 1999), the disease progresses over two to three months until death.

There are also several differential diagnoses that could be responsible for the lesions observed in Altai marmots, including parasitic or bacterial dermatitis (mainly due to *Staphylococcus* spp. or *Streptococcus* spp.), or even telogen defluxion (Panic *et al.*, 1992). As far as we are aware, *Sarcoptes scabiei* has never been recorded in marmots but is present in other rodents (e.g. North American porcupines (Clair *et al.*, 2024)). However, the observed lesions could be consistent with parasitic dermatitis caused by gamasids, particularly the mite *Hirstionyssus blanchardi* reported in marmots in Europe, Russia and Kazakhstan (Senotrusova & Kapitonov, 1970; Vinarski & Korallo-Vinarskaya, 2017; Vinarski & Korallo-Vinarskaya, 2020). To our knowledge, these are the first observations of such clinical presentations on Altai marmots in Kyrgyzstan.

## Statistics

Statistical analyses were conducted in R software to investigate variation in the detection of suggestive skin lesions among species, over time, and between study areas. Chi-square tests revealed significant temporal variation for all species in both reserves (all  $P < 0.001$ ), indicating strong interannual fluctuations. Binomial generalized linear models showed significant differences in lesion detection between reserves for all species (all  $P < 0.001$ ), with contrasting spatial patterns: marmots exhibited higher prevalence of mange-like cutaneous affection in Naryn Reserve, whereas ibexes showed higher prevalence in Sarychat-Eertash Reserve. Snow leopards consistently displayed low prevalence. Year-specific comparisons between reserves were conducted using either proportion tests or Fisher's exact tests, depending on the sample size. These analyses showed that differences between reserves were species-dependent and varied across years. In marmots, significant differences between reserves emerged from 2019 onwards. For ibex, significant differences emerged in most years between 2018 and 2024. In snow leopards, differences between reserves were intermittent and only significant in a subset of years. Comparisons among species within each reserve and year revealed significant differences in nearly all cases (all adjusted  $P < 0.01$ ), highlighting consistent interspecific variation. Spearman correlation tests were performed on species-specific disease prevalence across reserve-year units to assess potential interspecific relationships. No significant correlations were detected (all  $P > 0.5$ ), suggesting that disease dynamics were independent among species.

Finally, a generalized linear mixed model was used to evaluate the combined effects of species and reserve. This revealed significant effects of species and reserve, as well as their interaction (all  $P < 0.001$ ). Disease prevalence was highest in marmots, intermediate in ibex, and lowest in snow leopards. The significant interaction effect indicated that spatial patterns differed among species, with opposite trends observed between marmots and ibex. The random effect of year confirmed substantial interannual variability. Overall, these results demonstrate that disease prevalence is strongly influenced by species identity, spatial context, and time.

Disease prevalence showed substantial variability across years, ranging from near zero to over 50%, consistent with episodic outbreak dynamics. The infections in question appear to be well established in the environment and among the populations, with a high rate of recurrence over time. However, the frequency of severe cases observed varies greatly and depends heavily on location. This is consistent with the influence of environmental factors on the manifestation of the disease, as well as transmission between people in close contact. However, surprisingly, according to our data, there is currently no evidence of coordinated interspecific dynamics. We were unable to establish a statistical link between visible lesions in ibex, marmots and snow leopards within the same area and in the same year. The agents likely to cause skin conditions of this type are predominantly parasitic and are transmitted through direct or indirect contact (such as marmots sharing a burrow, resting areas used by groups of ibexes, or prolonged close contact, for example, between a

leopard and its prey over several days whilst the leopard is feeding on it). At this stage, we can neither confirm nor rule out any routes of transmission.

## Limitations and uses of camera traps

A key limitation of our study is the absence of further investigations to definitively diagnose the causative agent(s) responsible for the observed lesions. Furthermore, the dense fur of the species studied greatly limits the visibility of skin lesions. These only become visible in the most severe cases, necessarily in conjunction with alopecia. Additionally, the distance of the animals from the camera traps, lighting conditions and framing do not always permit interpretation of the images, resulting in a significant loss of information. Therefore, the sensitivity for detecting suggestive skin lesions is relatively low using camera trap analysis. In the case of sarcoptic mange, many infected animals remain subclinical or present with subacute signs (Pence & Ueckermann, 2002), so that they are unlikely to be detected by camera trapping. Thus, we can hypothesise that a lower detection rate for suggestive skin lesions does not necessarily imply a lower prevalence of infection in the studied animal populations. In fact, in populations where sarcoptic mange has become endemic, clinical cases become frequent but less severe (Pence & Ueckermann, 2002) and may therefore be undetectable by camera trapping. This could explain the great decrease in detection date in Siberian ibex, among whom mange has become endemic in recent years in the Sarychat-Eertash area (Vyrypaev, 1985). Conversely, an increase in the incidence of severe lesions detected by camera trapping within a population may also indicate exposure to aggravating factors, such as suboptimal environmental conditions, malnutrition, stress, immunosuppression, or other diseases, which should then be investigated (Pence & Ueckermann, 2002). Therefore, analysis of camera trap data does not appear to allow conclusions to be drawn about changes in the infection rate within a population over time.

However, our study has shown how this non-invasive tool can be used for sanitary surveillance, to detect the occurrence of some diseases, assess affected species, and formulate hypotheses about the causative agents involved and the severity of their consequences for the population (e.g., assessment of morbidity in cases of severe infection and mortality). This also helps to understand the presence of new threats to the studied species, learn more about their potential seasonal nature, the profile of affected individuals and the most affected geographical areas. Such close and long-term monitoring could highlight determining factors such as different weather patterns, increasing contact between wildlife and domestic animals, or varying food availability for prey and predators, for example. Ultimately, this type of monitoring may help to guide future research into pathogens in domestic animals, livestock and any wild animal carcasses found in relevant geographical areas. It could facilitate their study and thus help control such threats to the ecosystem. OSI-Panthera is the only NGO program conducting year-round long-term camera trap monitoring in these reserves, and the resulting dataset is extremely valuable.

## Mange

Mange is a skin disease in mammals caused by infestation with parasitic mites. These mites burrow into the skin or live on its surface, leading to intense itching, hair loss, skin thickening or crusting, inflammation and secondary infections. Several types of mange exist, but the most described in wildlife and domestic animals worldwide is Sarcoptic mange, caused by *Sarcoptes scabiei* mites, which is highly contagious and can affect a wide range of species including dogs, foxes, wolves, and even humans (Escobar *et al.*, 2022; Guillot *et al.*, 2023). In some naïve populations, transmission of this agent can cause significant enzootic diseases with serious consequences for the health and survival of individuals. Infestation with this mite has been reported in Siberian ibex, and several suspected cases have been reported in snow leopards presenting with suggestive dermatological lesions associated with very poor body condition.

Furthermore, it is important to note the predatory relationships between the affected species, as diseases affecting marmots and ibexes could pose health risks to snow leopards and other predators through direct disease transmission during feeding, or a reduction in the number of these prey in case of mortality. Increased contact between domestic and wild animals can pose significant health threats to both groups (Mishra *et al.*, 2022). In the case of mange infections, parasites can be transmitted by direct or indirect contact, since mites can survive off their previous host and remain infective for a new one (Pence & Ueckermann, 2002). For instance, in humid conditions and at a relatively cool temperature of 10°C, *Sarcoptes scabiei* mites can survive off a host for up to 19 days. Their survival rate is lower outside of these conditions (Browne *et al.*, 2021).

In Central Asia, sarcoptic mange appears to be becoming endemic in some ibex populations, suggesting that sustained transmission may now occur within wild hosts themselves rather than relying solely on repeated spillover from livestock (Vyrypaev, 1985). Various episodes of sarcoptic mange have been reported in Siberian ibex in Kyrgyzstan since 1957, resulting in significant mortalities and population impacts (Vyrypaev, 1985). Sarcoptic mange can pose a serious threat to isolated, fragmented or small populations (León-Vizcaíno *et al.*, 1999). For snow leopards, even sporadic cases have the potential to remove key individuals and thereby exert an immediate impact on the viability of local populations. As with many other diseases, environmental factors can exacerbate clinical sarcoptic mange (Pence & Ueckermann, 2002). Extreme or atypical weather conditions (such as shifts in temperature or humidity associated with climate change), as well as food depletion (including reduced prey availability, impaired hunting ability, or grazing competition with livestock) may intensify disease risks.

## Conservation

These observations highlight the importance of conservation measures at a time of expanding land use (e.g., pastoralism and mining), habitat fragmentation, climate change, and globalization, that are increasing the risks of emerging infectious diseases in high-mountain ecosystems of Central Asia. They also highlight the urgent need for research on dis-

eases affecting snow leopards and their prey, with an evaluation of their conservation impacts. We believe that a holistic “One Health” approach is increasingly essential, one that addresses livestock health, mitigates transmission to wildlife and integrates ecological, environmental, and societal dimensions.

## Conclusion

Since 2012 and 2016, respectively, camera traps in the Sarychat-Eertash and Naryn State Nature Reserves have documented mange-like skin lesions on snow leopards, Altai marmots and Siberian ibexes. These observations raise concerns about potential disease transmission and spread among animal populations within Kyrgyzstan’s protected areas. They highlight the need for targeted research to confirm the causative agents, evaluate their epidemiology and implications for wildlife conservation, particularly in the context of increasing risk of emerging infectious diseases in the high-mountain ecosystems of Central Asia.

**Acknowledgments** We would like to acknowledge the Sarychat-Eertash and Naryn Nature State Reserves management teams and the rangers for making our studies possible. We also want to acknowledge our local partners and the Department of Biodiversity Conservation and Specially Protected Natural Territories under the Ministry of Natural Resources, Ecology and Technical Supervision of the Kyrgyz Republic, for supporting the program. We thank Pr Gregorio Mentaberre Garcia and his team for having accepted to share their experiences with us. Finally, we thank the staff members of Objectif Sciences International NGO, particularly Anne Ouvrard who has been the manager of this citizen project during many years, and all the volunteers of the OSI-Panthera missions for their scientific and financial support.

**Specimen collection** Authorizations to set up camera traps and collect data in the Nature State Reserves of Sarychat-Eertash and Naryn were given to OSI-Panthera program by the Nature State Reserves themselves and by the Department of Biodiversity Conservation and Specially Protected Natural Territories under the Ministry of Natural Resources, Ecology and Technical Supervision of the Kyrgyz Republic.

**Funding** Project led without any external funding. Funds were obtained within the frame of OSI-Panthera volunteering field expeditions through donations of the participants.

**Conflict of interest** All authors declare no conflict of interest in this research.

**Author contribution** JFPM: Writing – original draft, review & editing, data analysis; MG: Writing – review and editing; CL: Writing – review and editing, data analysis; BC: Writing – review and editing, data collection; BA: Writing – review and editing; ALC: Supervision, writing – review and editing, data collection.

**Received** 3 December 2025 | **Revised** 28 April 2026

**Accepted** 6 May 2026 | **Published online** 20 May 2026

## References

Arbaev KS, Azhybekov BS, Aydraliev OK, Tolkunbek A, Amirakulov MM. 2017. Mycosporidiosis of the snow leopard in the Kyrgyz

- Republic. *LXIV International Correspondence Scientific and Practical Conference 'Scientific Discussion: Innovations in the Modern World'*, 4(63): 84–90. Link: <https://www.internauka.org/authors/amirakulov-marasulbek-maaraimbekovich>. Downloaded: March 2025.
- Bornstein S, Mörner T, Samuel WM. 2001. *Sarcoptes scabiei* and Sarcoptic Mange. In: Samuel WM, Pybus MJ, Kocan AA (eds). *Parasitic Diseases of Wild Mammals*. 2<sup>nd</sup> ed. Ames: Iowa State University Press. Pp107–119.
- Browne E, Driessen MM, Ross R, Roach M, Carver S. 2021. Environmental suitability of bare-nosed wombat burrows for *Sarcoptes scabiei*. *International Journal for Parasitology: Parasites and Wildlife*, 10(16): 37–47. DOI: [10.1016/j.ijppaw.2021.08.003](https://doi.org/10.1016/j.ijppaw.2021.08.003).
- Carricondo-Sanchez D, Odden M, Linnell JDC, Odden J. 2017. The range of the mange: Spatiotemporal patterns of sarcoptic mange in red foxes (*Vulpes vulpes*) as revealed by camera trapping. *PLoS One*, 12(4): e0176200. DOI: [10.1371/journal.pone.0176200](https://doi.org/10.1371/journal.pone.0176200).
- Clair LS, Hopf-Dennis C, Peters-Kennedy J, Lucio-Forster A, Childs-Sanford S. 2024. Sarcoptic mange in free-ranging North American porcupines (*Erethizon dorsatum*) in New York State. *Journal of Zoo and Wildlife Medicine*, 54(4): 855–864. DOI: [10.1638/2023-0060](https://doi.org/10.1638/2023-0060).
- Dagleish MP, Ali Q, Powell RK, Butz D, Woodford MH. 2007. Fatal *Sarcoptes scabiei* infection of blue sheep (*Pseudois nayaur*) in Pakistan. *Journal of Wildlife Diseases*, 43(3): 512–517. DOI: [10.7589/0090-3558-43.3.512](https://doi.org/10.7589/0090-3558-43.3.512).
- DNPWC & DoFSC [Department of National Parks and Wildlife Conservation and Department of Forests and Soil Conservation]. 2024. Snow Leopard conservation action plan for Nepal (2024–2030). Department of National Parks and Wildlife Conservation and Department of Forests and Soil Conservation, Kathmandu, Nepal. Link: [https://dnpwc.gov.np/media/publication/Snow\\_Leopard\\_Conservation\\_Action\\_Plan\\_2024-2030.pdf](https://dnpwc.gov.np/media/publication/Snow_Leopard_Conservation_Action_Plan_2024-2030.pdf).
- Escobar LE, Carver S, Cross PC, Rossi L, Almberg ES, Yabsley MJ, Niedringhaus KD, Van Wick P, Dominguez-Villegas E, Gakuya F, Xie Y, Angelone S, Gortázar C, Astorga F. 2022. Sarcoptic mange: an emerging panzootic in wildlife. *Transboundary and Emerging Diseases*, 69: 927–942. DOI: [10.1111/tbed.14082](https://doi.org/10.1111/tbed.14082).
- Fletcher KC. 1978. Notoedric mange in a litter of snow leopards. *Journal of the American Veterinary Medical Association*, 173(9): 1231–1232. DOI: [10.2460/javma.1978.173.09.1231](https://doi.org/10.2460/javma.1978.173.09.1231).
- Fletcher KC. 1980. Demodicosis in a group of juvenile snow leopards. *Journal of the American Veterinary Medical Association*, 177(9): 896–898. DOI: [10.2460/javma.1980.177.09.896](https://doi.org/10.2460/javma.1980.177.09.896).
- Grob H, Wyss F, Wenker C, Uhrlass S, Krüger C, Mayser P, Nenoff P. 2018. *Trichophyton mentagrophytes* – vom Schneeleoparden zum Menschen. *Der Hautarzt*, 69(12): 1021–1032. DOI: [10.1007/s00105-018-4234-2](https://doi.org/10.1007/s00105-018-4234-2).
- Guillot J, Losson B, Delsart M, Briand A, Fang F, Rossi L. 2023. Sarcoptic mange in wild and domestic animals. In: Fischer K, Chosidow O (eds). *Scabies*. Springer, Cham. Pp 313–343. DOI: [10.1007/978-3-031-26070-4\\_23](https://doi.org/10.1007/978-3-031-26070-4_23).
- Hameed K, Angelone-Alasaad S, Din JU, Nawaz M, Rossi L. 2016. The threatening but unpredictable *Sarcoptes scabiei* first deadly outbreak in the Himalayan lynx, *Lynx lynx isabellinus*, from Pakistan. *Parasites & Vectors*, 9: 402. DOI: [10.1186/s13071-016-1685-0](https://doi.org/10.1186/s13071-016-1685-0).
- Kubanychbekov Z, Sharma K, Zhumabai uulu K, Wearn O, Durbach I, Raulerson M, Kochorov C, Asykulov T, Koshkin M, Zhumabay kyzy G, Eldiär K. 2026. Snow leopard (*Panthera uncia*) status in Kyrgyzstan. *Snow Leopard Reports*, 5: 26–33. DOI: [10.56510/slr.v5.63883](https://doi.org/10.56510/slr.v5.63883).
- León-Vizcaíno L, Ruíz de Ybáñez MR, Cubero MJ, Ortíz JM, Espinosa J, Pérez L, Simón MA, Alonso F. 1999. Sarcoptic mange in Spanish ibex from Spain. *Journal of Wildlife Diseases*, 35(4): 647–659. DOI: [10.7589/0090-3558-35.4.647](https://doi.org/10.7589/0090-3558-35.4.647).
- Mishra C, Samelius G, Khanyari M, Prashanth NS, Low M, Esson C, Venkatachalam S, Johansson Ö. 2022. Increasing risks for emerging infectious diseases within a rapidly changing High Asia. *Ambio*, 51(3): 494–507. DOI: [10.1007/s13280-021-01599-7](https://doi.org/10.1007/s13280-021-01599-7).
- Ostrowski S, Gilbert M. 2016. Diseases of Free-Ranging Snow Leopards and Primary Prey Species. In: Mallon D, McCarthy T, Nyhus PJ (eds). *Snow Leopards*, 1<sup>st</sup> ed. Pp 97–112. DOI: [10.1016/B978-0-12-802213-9.00009-2](https://doi.org/10.1016/B978-0-12-802213-9.00009-2).
- Pamir Times. (2011, February). Sick snow leopard captured by villagers in Skardu, dies. <https://pamirtimes.net/2011/02/27/sick-snow-leopard-captured-by-villagers-in-skardu-dies/>. Downloaded: March 2025.
- Panic R, Scott DW, Tennant BC, Anderson WI, Johnson M. 1992. Skin disorders of the laboratory woodchuck (*Marmota monax*): a retrospective study of 113 cases (1980–1990). *The Cornell veterinarian*, 82(4): 405–421.
- Pence DB, Ueckermann E. 2002. Sarcoptic mange in wildlife. *Revue scientifique et technique (International Office of Epizootics)*, 21: 385–398. DOI: [10.20506/rst.21.2.1335](https://doi.org/10.20506/rst.21.2.1335).
- Peters JC, Zwart P. 1973. Sarcoptic mange in snow leopards. *Erkrankungen der Zootiere*, 15: 333–334.
- Senotrusova VN, Kapitonov VI. 1970. Gamasid mite, *Hirstionyssus blanchardi*, a parasite of marmots in Kazakhstan. *Parazitologiya*, 4(2): 166–170.
- Vinarski MV, Korralo-Vinarskaya NP. 2017. An annotated catalogue of the gamasid mites associated with small mammals in Asiatic Russia. The family Haemogamasidae (Acari: Mesostigmata: Gamasina). *Zootaxa*, 4273(1): 1–18. DOI: [10.11646/zootaxa.4273.1.1](https://doi.org/10.11646/zootaxa.4273.1.1).
- Vinarski MV, Korralo-Vinarskaya NP. 2020. An annotated catalogue of the gamasid mites associated with small mammals in Asiatic Russia. The family Hirstionyssidae (Acari: Mesostigmata: Gamasina). *Zootaxa*, 4838(1): 102–118. DOI: [10.11646/zootaxa.4838.1.5](https://doi.org/10.11646/zootaxa.4838.1.5).
- Vyrypaev VA. 1985. The influence of epizootic of *Sarcoptes* infection on the population of central Asian mountain ibex in Tien-Shan. *Parazitologiya*, 19(3): 190–194. Link: <http://archive.org/details/parazitologiya-19-190-194>.